

## Regional methods of anesthesia in labor pain relief: a systematic review

O.A. Makcharin<sup>1</sup>, E.A. Lebedeva<sup>1\*</sup>, N.V. Kochubeinik<sup>1</sup>

Rostov State Medical University, Rostov-on-Don, Russia

### Abstract

**INTRODUCTION:** Today epidural anesthesia is the "golden standard" of anesthesia. But what can we do if the application of an epidural catheter is contraindicated? The use of narcotic analgesics can hardly be deemed a worthy alternative. **OBJECTIVE:** To identify alternative regional methods of anesthesia in labour pain relief. **MATERIALS AND METHODS:** We have performed a systematic review of literature in accordance with the PRISMA (Preferred Reporting Items for Systematic reviews and Meta-Analyses) guideline principles. The bibliographic search was conducted in January-March 2022. The search was performed in the MEDLINE, EMBASE, eLibrary.ru, Cochrane Library databases. The search keywords were: anesthesia of childbirth, pudendal block, paracervical block, paravertebral block, quadratus lumborum (QLB) block, erector spinae plane block (ESPB). We found 122 works, and after removing 94 works for various reasons, 28 works were analyzed. **RESULTS:** We found 122 works, and after removing 94 works for various reasons, 28 works were analyzed. We identified six randomized controlled trials related to the subject matter, but the endpoints were heterogeneous preventing a statistical analysis; therefore, we performed a qualitative review of the literature. Works dedicated to paravertebral and paracervical blocks showed sufficient effectiveness of anesthesia for the second period of labor. Good results of anesthesia of the second period of labor were also described with the use of ESPB and bilateral QLB. Nevertheless, it is impossible to draw statistically significant conclusions on the use of ESPB and QLB due to the small sample. Articles devoted to the use of pudendal block in labour revealed its low effectiveness. **CONCLUSIONS:** The described results show that paravertebral, ESPB and QLB blocks can be used as alternative regional methods of anesthesia in labour. However, further research is required to assess the effectiveness of their use in childbirth.

## Проводниковые методы обезболивания родов: систематический обзор

О.А. Махарин<sup>1</sup>, Е.А. Лебедева<sup>1\*</sup>, Н.В. Кочубейник<sup>1</sup>

ФГБОУ ВО «Ростовский государственный медицинский университет» Минздрава России, Ростов-на-Дону, Россия

### Реферат

**АКТУАЛЬНОСТЬ:** Эпидуральная анальгезия на сегодняшний день является «золотым стандартом» обезболивания родов. Но что делать, если установка эпидурального катетера противопоказана? Использование наркотических анальгетиков трудно считать достойной альтернативой в акушерстве. **ЦЕЛЬ ИССЛЕДОВАНИЯ:** обобщить имеющиеся литературные данные об альтернативных региональных методах обезболивания родов. **МАТЕРИАЛЫ И МЕТОДЫ:** Мы провели систематический обзор литературы в соответствии с руководящими принципами PRISMA (Preferred Reporting Items for Systematic Reviews and Meta-Analyses — предпочтительные параметры отчетности для систематических обзоров и метаанализа). Библиографический поиск был проведен в январе-марте 2022 г. Поиск производился в базах MEDLINE, EMBASE, eLibrary.ru, Cochrane Library. Поисковыми терминами были: обезболивание родов, блокада полового нерва, парацервикальная блокада, паравертебральная блокада, блокада квадратной мышцы поясницы (quadratus lumborum block — QLB), блокада мышцы, разгибающей позвоночник (erector spinae plane block — ESPB). Были найдены 122 работы, после удаления по различным причинам 96 работ проанализированы 26 полнотекстовых статей. **РЕЗУЛЬТАТЫ:** Нами обнаружено шесть рандомизированных контролируемых исследований, посвященных данному вопросу. Их конечные результаты были неоднородными, что препятствовало статистическому анализу, поэтому мы провели качественный обзор литературы. Работы, посвященные паравертебральной и парацервикальной блокадам, показали достаточную эффективность обезболивания второго периода родов. Также хорошие результаты обезболивания второго периода родов описаны при использовании ESPB и билатеральной QLB. Тем не менее статистически значимых выводов по применению ESPB и QLB сделать невозможно ввиду малой выборки. Статьи, посвященные использованию блокады полового нерва в родах, показали ее невысокую эффективность. **Выводы:** Описанные результаты показывают, что в качестве альтернативных

**KEYWORDS:** obstetric anesthesia, nerve block, pudendal blockade, systematic review

\* *For correspondence:* Elena A. Lebedeva — Dr. Med. Sci., associate professor, head of the Department of anesthesiology and reanimatology, Rostov State Medical University, Rostov-on-Don, Russia; e-mail: okulus@yandex.ru

✉ *For citation:* Makcharin O.A., Lebedeva E.A., Kochubeinik N.V. Regional methods of anesthesia in labor pain relief: a systematic review. *Annals of Critical Care.* 2022;4:55–65. <https://doi.org/10.21320/1818-474X-2022-4-55-65>

📅 *Received:* 20.05.2022

📅 *Accepted:* 05.09.2022

📅 *Published online:* 28.10.2022

региональных методов обезболивания родов могут быть использованы паравертебральная блокада, ESPB и QLB. Однако для оценки эффективности их применения в родах требуются дальнейшие исследования.

**КЛЮЧЕВЫЕ СЛОВА:** анестезия в акушерстве, блокада полового нерва, блокады периферических нервов, систематический обзор

\* *Для корреспонденции:* Лебедева Елена Александровна — д-р мед. наук, доцент, заведующая кафедрой анестезиологии и реаниматологии ФГБОУ ВО «Ростовский государственный медицинский университет» Минздрава России, Ростов-на-Дону, Россия; e-mail: okulus@yandex.ru

✉ *Для цитирования:* Махарин О.А., Лебедева Е.А., Кочубейник Н.В. Проводниковые методы обезболивания родов: систематический обзор. *Вестник интенсивной терапии им. А.И. Салтанова.* 2022;4:55–65. <https://doi.org/10.21320/1818-474X-2022-4-55-65>

📅 *Поступила:* 20.05.2022

📅 *Принята к печати:* 05.09.2022

📅 *Дата онлайн-публикации:* 28.10.2022

DOI: 10.21320/1818-474X-2022-4-55-65

## Introduction

Over the past 10 years, the approach to the problem of labor pain relief has changed significantly. The development of regional methods of anesthesia, as well as significant side effects and lack of effectiveness of narcotic analgesics, have led to the fact that epidural anesthesia has become the “gold standard” for labor pain relief [1]. The basis for this was the ability to effectively affect all parts of the pathways from the nociceptors involved during childbirth. At the same time, despite obvious advantages of epidural anesthesia in childbirth, such as controllability, high-quality analgesia, lack of effect on the fetus, its use is impossible in some situations, such as thrombocytopenia, coagulopathy and a number of other conditions. The steady increase in the number of pregnant women with comorbidities, in which the installation of an epidural catheter is contraindicated, requires the development of an additional standard for labor pain relief in such women.

**Objectives of this review** was to summarize the available data on alternative conduction methods of labor pain relief.

## Materials and methods

We synthesized data on the use of paracervical block, pudendal nerve block, bilateral paravertebral block, quadratus lumborum block (QLB), and erector spinae plane block (ESPB) for labor pain relief. A search was made for articles on conductive methods of labor pain relief in the Pubmed, EMBASE, eLibrary.ru and Cochrane Library databases, published in the period from 1982 to 2021. The search keywords were pudendal nerve block, paracervical block, paravertebral block, quadratus lumborum block, erector spinae plane block, anesthesia of childbirth. Literature data search was carried out by two researchers. In the event of disagreement regarding the inclusion of an article in the review, a decision on a particular article was made collectively with the participation of the entire team of authors. The study was performed in accordance with the PRISMA (Preferred Reporting Items for Systematic Reviews and Meta-Analyses) international guidelines for writing systematic reviews and meta-analyses [2]. During the second stage, the authors reviewed abstracts of articles and excluded publications that did not meet the study criteria. Criteria for inclusion in the review are presented in Table 1.

**Table 1.** Criteria for inclusion in the systematic review

Parameter	Inclusion criteria
Patients	Women in labor over 18 years of age
Interventions	Epidural anesthesia, paravertebral block, paracervical block, pudendal nerve block, erector spinae plane block, ql-block
Comparison	Comparison of pain relief between the above methods, or with an active or passive control group
Primary endpoint	Women's satisfaction with pain relief: verbal assessment, visual analog scale (VAS) or other pain scale, need for opioids
Secondary endpoint	Any perioperative complications of the above anesthesia methods
Study design	Randomized clinical trials, case series, clinical observation

During the third stage, the text of selected articles was analyzed in terms of compliance with the inclusion criteria and the list of references for the presence of relevant studies (Fig. 1).

## Results

122 papers were collected. After the analysis 8 papers were included in the review.

A summary of the studies included in the review is presented in Table 2.

## Assessing the risk of study bias

Each article included in the review was assessed for study bias, which was performed independently by three authors, and a final decision was made based on the results of a joint discussion. The parameters and results of the assessment are presented in Fig. 2 and Table 3.

As can be seen from Table 2, the review included articles on paracervical nerve block, pudendal nerve block, bilateral paravertebral block, erector spinae plane block, and bilateral quadratus lumborum block. Women's satisfaction with the quality of analgesia after performing the above blocks is described in Table 4 and their possible complications are presented in Table 5.

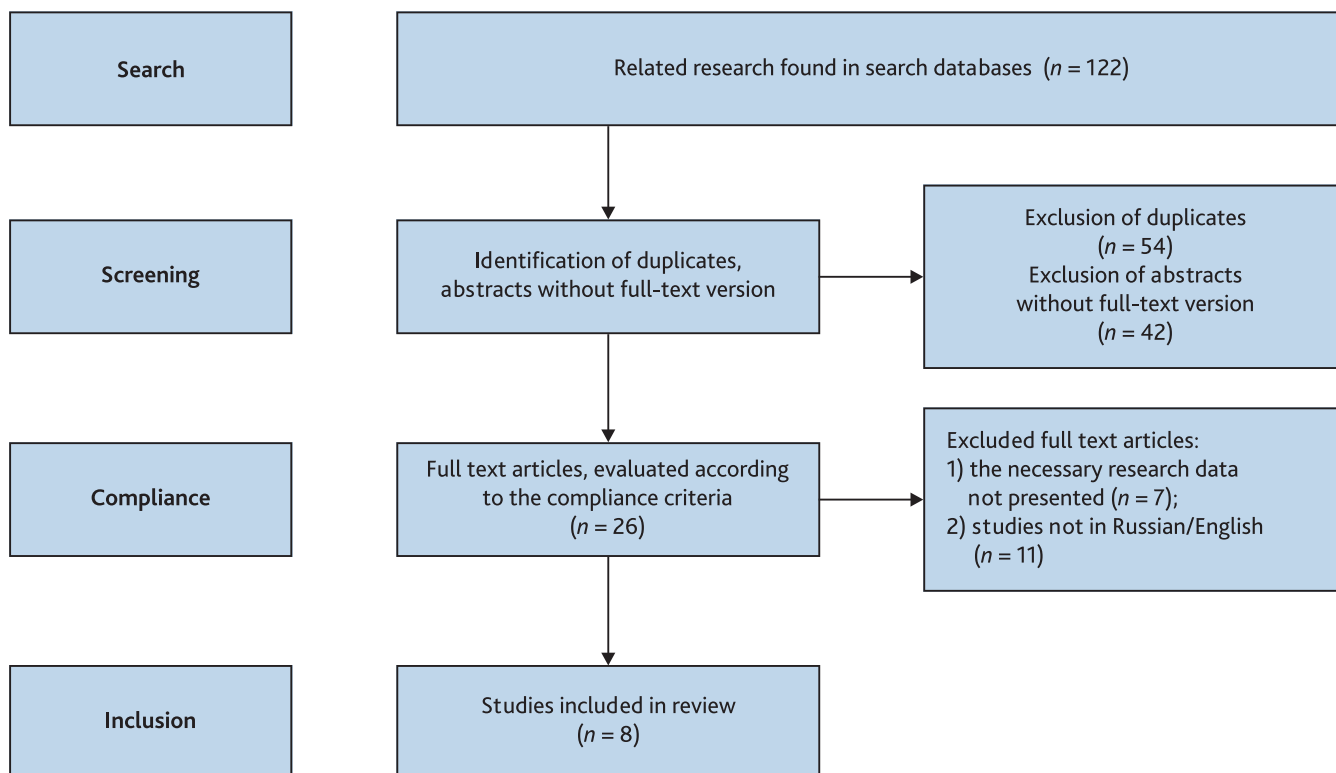


Fig. 1. PRISMA flowchart for choosing a study

**Table 2.** Characteristics of the included studies

Authors, study year	Sample size, <i>n</i>		Control group type	Study design	Anesthesia methods (medications, doses)
	Study group	Control group			
Shrivage J., Sinha R., 2001	100	98	Administering distilled water instead of anesthetic	Randomized, placebo-controlled trial	Paracervical block (2 % lidocaine — 20 ml) vs paracervical administration of distilled water 20 ml
Nikkola E. et al., 2000	7	5	Intravenous, patient-controlled fentanyl injection for labor pain management	Randomized controlled trial	Paracervical blockade (0.25 % bupivacaine — 10 ml) vs intravenous patient-controlled fentanyl injection
Jensen F. et al., 1984	55	62	Intramuscular meperidine 75 mg injection	Randomized controlled study	Paracervical blockade (0.25 % bupivacaine — 12 ml) vs intramuscular injection of 75 mg meperidine
Nikpoor P., Bain E., 2013	92	91	Spinal analgesia	Randomized controlled trial	Pudendal nerve block (1% lidocaine — 20 ml) vs spinal analgesia with 5 % lidocaine — 1 ml
Vilchis-Renteria J.S. et al., 2020	4	None	None	Clinical case series	1) 0.2 % ropivacaine solution 20 ml laterally 2) 2 % lidocaine solution 10 ml + 1:200 000 adrenaline solution monolaterally 3) 1.5 % lidocaine solution 20 ml + 1:200 000 adrenaline solution monolaterally 4) 0.5 % lidocaine solution 20 ml + 1:200 000 adrenaline monolaterally
de Haan J. et al., 2020	1	None	None	Clinical case	0.25 % bupivacaine solution — 20 ml bilaterally
Neimark M.I., Ivanova O.S., 2018	Group 1: epidural analgesia ( <i>n</i> = 40) Group 2: ultra-low dose spinal anesthesia ( <i>n</i> = 40) Group 3: paravertebral anesthesia ( <i>n</i> = 40)	40	Childbirth without anesthesia	Randomized controlled trial	Group 1: 0.2 % ropivacaine solution intermittent Group 2: 0.5 % ropivacaine hydrochloride solution Group 3: 0.5 % ropivacaine hydrochloride solution — 12 ml bilaterally
Antipin E.E. et al., 2014	Group 1: epidural analgesia ( <i>n</i> = 30) Group 2: lumbar paravertebral block ( <i>n</i> = 30)	30	Childbirth without anesthesia	Randomized controlled trial	Group 1: 0.2 % ropivacaine solution + 0.005 % fentanyl 2 mcg/ml microfluidic injection Group 2: 0.75 % ropivacaine solution, 10 ml each side

In works devoted to the use of paracervical blockade for labor pain relief, it was shown that the introduction of a local anesthetic into the submucosal layer of the vaginal fornix lateral to the cervix allows blocking the paracervical ganglion, which provides anesthesia for the uterus and its cervix. This block is effective for relieving pain during uterine contraction, but it does not affect sensitive afferent fi-

bers coming from the perineum. Thus, this block is not effective in the second stage of labor. The literature describes such complications and side effects as fetal bradycardia, systemic toxicity of local anesthetics, infection, and postpartum neuropathy [3–5]. A study with 198 women showed that paracervical blocks using 2 % lidocaine solution were more effective than placebo (relative risk [RR] 32.31; 95 %

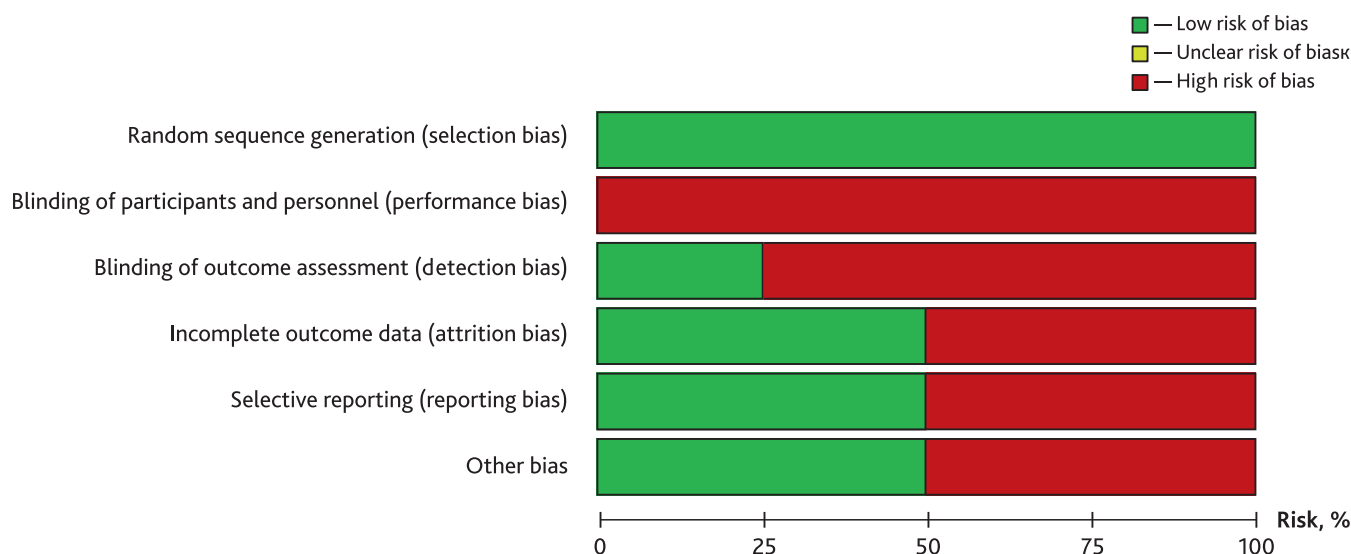


Fig. 2. Summary assessment of the risk of systematic errors

Authors, study year	Random sequence generation (selection bias)	Blinding of participants and personnel (performance bias)	Blinding of outcome assessment (detection bias)	Incomplete outcome data (attrition bias)	Selective reporting (reporting bias)	Other bias
de Haan J. et al., 2020	+	-	-	+	+	+
Jensen F. et al., 1984	+	-	+	+	-	-
Nikkola E. et al., 2000	+	-	+	-	-	-
Nikpoor P., Bain E., 2013	+	-	-	+	-	-
Shravage J., Sinha R., 2001	+	-	-	-	+	-
Vilchis-Renteria J.S. et al., 2020	+	-	-	+	+	+
Antipin E.E. et al., 2014	+	-	-	-	+	+
Neimark M.I., Ivanova O.S., 2018	+	-	-	-	-	+

Note: «+» — low risk of bias; «-» — high risk of bias.

confidence interval [95% CI] 10.60–98.54), at the same time, after performing paracervical block, such side effects on the part of the fetus as transient bradycardia were more often noted, and on the part of the mother — dizziness, sweating and tingling in the lower extremities [3]. Two other studies compared the use of paracervical block and narcotic analgesics for labor pain [4, 5]. E. Nikkola et al. (2000) conducted a randomized study comparing patient-controlled intravenous fentanyl with paracervical block (10 ml 0.25% bupivacaine) for labor pain relief [4]. The study was terminated after the participation of 12 women, as one newborn in the fentanyl group experienced a significant decrease in peripheral oxygen saturation to 59%, which required the administration

of naloxone. Episodes of neonatal desaturation (oxygen saturation level less than 90%) were more frequent in the opioid group compared to the paracervical block group. Mean and maximum neonatal heart rates, in addition to measures of neonatal neurologic and adaptive capacity, were lower in the opioid group. F. Jensen et al. (1984) conducted a randomized, double-blind study comparing the efficacy of paracervical block (12 ml of 0.25% bupivacaine) with intramuscular administration of 75 mg pethidine for labor pain relief. The authors showed that satisfaction with analgesia was higher in the group of women who underwent paracervical block compared with the group of women who received pethidine for pain relief (odds ratio [OR] 2.52; 95%

**Table 4.** Evaluation and comparison of the effectiveness of anesthesia methods

Authors, study year	Definition of effectiveness	Comparison	Measure of effectiveness
Shrivage J., Sinha R., 2001	VAS pain assessment	More pronounced analgesic in the paracervical block group compared with placebo	RR 32.31; 95 % CI [10.60–98.54]
Jensen F. et al., 1984	Verbal assessment of pain intensity	Better pain relief in the paracervical block group compared to the group treated with opioids at 20, 40 and 60 <sup>th</sup> minutes	OR 2.52; 95 % CI [1.65–3.83]
Nikpoor P., Bain E., 2013	Verbal assessment of change in pain intensity after intervention	Greater satisfaction in the spinal analgesia group compared to the group where the pudendal nerve block was performed	100 % vs 29 % OR 3.36; 95 % CI [2.46–4.60]
Nikkola E. et al., 2000	Verbal assessment of change in pain intensity after intervention	Decrease in pain intensity after administration of block in all clinical cases	None
Vilchis Rentería J.S., 2020	Individual VAS pain assessment	Decrease in pain intensity after administration of block in all clinical cases	None
de Haan J. et al., 2020	Patient's individual assessment of pain intensity according to VAS	Decrease in pain intensity after administration of block	None
Neimark M.I., Ivanova O.S., 2018	Satisfaction with pain relief (assessment of the effectiveness of pain relief on the scale of N.N. Rasstrigin and B.V. Schneider, 1974–1975), assessment of hemodynamic parameters	More pronounced analgesic effect in the epidural and paravertebral analgesia groups compared with the control group and the low-dose spinal anesthesia group. Decrease in mean BP in the group of epidural paravertebral and low-dose spinal anesthesia compared to the control group	None
Antipin E.E. et al., 2014	VAS pain assessment	More pronounced analgesic effect in the group of epidural analgesia compared to the group in which paravertebral block was performed	None

**Table 5.** Complications described in the studies

Complications	Study
<b>For the mother</b>	
Dizziness, sweating and tingling in the lower extremities	Shrivage J., Sinha R., 2001
<b>For the fetus/newborn</b>	
Transient bradycardia in the fetus	Shrivage J., Sinha R., 2001
Fetal desaturation episodes	Jensen F. et al., 1984 Nikkola E. et al., 2000

CI 1.65–3.83) [5]. Similar conclusions were reached by the authors of a Cochrane review aimed at establishing the efficacy and safety of paracervical block for labor pain relief by combining data from the above studies [6]. It has been shown that paracervical block compared with opioids did not lead to an increase in the frequency of operative vaginal delivery (OR 1.02; 95 % CI 0.56–1.87) or caesarean section (RR 0.23; 95 % CI 0.03–1.87). None of the newborns had an Apgar

score less than 7 at 5 minutes postpartum [4, 5]. The difference in need for additional analgesia between the group in which women underwent paracervical block and the group in which women received opioids for pain relief in the first stage of labor was not statistically significant (OR 1.73; 95 % CI 0.54–5.50) [6]. Thus, the data obtained indicate that paracervical blockade provides more effective analgesia compared with placebo and narcotic analgesics during labor.



## Pudendal nerve block

A pudendal nerve block can be used to reduce pain in the second stage of labor, as well as to suture an episiotomy. The nerve can be accessed using a transvaginal (most common) or percutaneous (perineal) approach. Variants of pudendal nerve block performed under ultrasound guidance have been described, but their use in obstetrics requires further research [7, 8]. The pudendal nerve arises from the S2–S4 segments and provides sensory innervation to the perineum, vulva, and lower vagina. Blockade of the pudendal nerve provides good analgesia in the second stage of labor, but does not reduce the intensity of pain during contractions in the first period. This method described complications such as bleeding, infection, and systemic toxicity of the anesthetic. Traditionally, obstetricians used pudendal nerve blocks to relieve pain and facilitate operative vaginal delivery in the absence of epidural analgesia, and also when epidural analgesia is not sufficiently effective. C. Hutchins (1980) compared the effectiveness of spinal analgesia and pudendal nerve block in 183 women who underwent operative vaginal delivery [9]. It was shown that none of the women in labor in the spinal anesthesia group experienced pain. At the same time, 62% of women in labor among those who underwent pudendal nerve block experienced discomfort, and 15% experienced severe pain during operative vaginal delivery. A similar conclusion was reached by P. Nikpoor and E. Bain (2013) in their systematic review, which was aimed at assessing the effectiveness and safety of various analgesics and methods available for operative vaginal delivery. The authors demonstrated that spinal analgesia more effectively relieved pain during childbirth compared to pudendal nerve block (OR 3.36; 95% CI 2.46–4.60) were satisfied with the quality of analgesia [10]. Thus, pudendal nerve blocks should be considered for second stage pain relief only if there are contraindications to neuraxial methods, or if epidural analgesia is not sufficiently effective in the second stage of labor.

## Paravertebral block

A search of literature in Russian language identified a few works devoted to the use of bilateral paravertebral block for labor pain relief [11, 12]. Several techniques for performing paravertebral blocks were described, which can be divided into blind techniques, techniques using neurostimulators, and blocks performed under ultrasound guidance [12–19]. The latter (using ultrasound) are considered more effective and safer due to a clear visualization of the needle tip in the paravertebral space, especially when it comes to thoracic paravertebral blockade, since the use of ultrasound navigation significantly reduces the risk of pleural puncture [20, 21]. Verification of the anesthetic administration under ultrasound showed that the anesthet-

ic in the paravertebral space spreads caudally, cranially, epidurally, and also along the contralateral paravertebral space, which provides blockade of the ipsilateral, segmental, somatic and sympathetic nerves in adjacent dermatomes [22–26]. It was shown that bilateral paravertebral block during labor provided effective analgesia during the second stage of labor [11, 12]. It should be noted that these works describe a single paravertebral bilateral administration of an anesthetic. Thus, M.I. Neimark and O.S. Ivanova (2018) compare the effectiveness of epidural, paravertebral (single injection on both sides of the spinal column) and low-dose spinal analgesia. The study included 160 women in labor. This study revealed that epidural analgesia and bilateral paravertebral block were more effective methods of pain relief in the second stage of labor ( $p < 0.05$ ) compared to low-dose spinal analgesia and placebo, since low-dose spinal analgesia quickly lost its effectiveness ( $p < 0.001$ ). The authors noted that in the group of women who underwent bilateral paravertebral analgesia, some women in labor noted intense fetal pressure on the perineum, but none of them required additional anesthesia in the second stage of labor [12].

## The erector spinae plane block

The erector spinae plane block (ESPB) was first described as a treatment for neuropathic chest pain. Subsequently, this block began to be used for pain relief in the cervical spine, after abdominal surgery and for pain in the lumbar region [27, 28]. This diversity of indications is explained by the distribution of local anesthetic after administration in the paravertebral and epidural spaces, both in the cranial and caudal directions, which causes both somatic and visceral analgesia in several segments [29]. With this block, the needle rests against the transverse process of the vertebra, the anesthetic is injected between the transverse process and the muscle the erector spinae plane. In addition to its technical simplicity, the relative distance from the spinal canal may mitigate potentially serious complications associated with neuraxial techniques. However, the use of this blockade for labor pain relief has been little studied to date. The literature describes isolated clinical observations of the use of this block for labor pain relief. Only 4 cases of the use of erector spinae plane block for labor pain relief have been described. Attention is drawn to the fact that after the implementation of this block, women in labor assessed the intensity of the pain syndrome on a numerical rating scale at 4–5 points [30]. Thus, the effectiveness of this technique requires further study.

A case of using a posterior block of the quadrant lumbar muscle in a woman in labor with hemophilia was also described [31]. This article provides details on the use of the third type of QLБ, in which the anesthetic is injected

in front of the quadrant lumbar muscle in the area where it reaches the transverse process of the fourth lumbar vertebra. In this type of QLB, the anesthetic spreads between the quadrant lumborum and the psoas major. With this approach, a classic trefoil is visible: the transverse process of the fourth lumbar vertebra looks like a stalk, the psoas major muscle is the anterior leaflet, the extensor muscle is the posterior leaflet, and the quadrant muscle is lateral leaflet [32, 33]. It should be noted that QLB is used as an effective method of pain relief in the early post-operative period after caesarean section [34–39], gynecological operations, primarily after hysterectomy [40], resection of the small [41] and large intestine [42, 43], nephrectomy [44–46], gastrectomy [47], hernioplasty [48, 49]. Quadrus abdominis block has been described after bifemoral shunting [50] and during operations on the lumbar spine [51, 52]. All authors showed in their works high patient satisfaction with the quality of pain relief after performing this block (patients noted a significant decrease in the intensity of the pain syndrome). However, we found a description of only 1 case of the use of QLB in childbirth in the literature available to us. At the same time, the authors note that the woman was satisfied with the quality of anesthesia [31]. However, the possibility of using this blockade for labor pain relief also requires further study.

#### Author's ORCID:

Makharin O.A. — 0000-0002-1700-0993

Lebedeva E.A. — 0000-0001-8375-7743

## References

- [1] Куликов А.В., Шифман Е.М. Анестезия, интенсивная терапия и реанимация в акушерстве и гинекологии. Клинические рекомендации. Протоколы лечения. Изд. 2-е, доп. и перераб. М.: Медицина, 2017. С. 153–68. [Kulikov A.V., Shifman E.M. Anesthesia, intensive care and reanimatology in obstetrics and gynecology. Clinical recommendations. Treatment protocols. The second edition, supplemented and revised. M.: Medicine, 2017. P. 153–68. (In Russ)]
- [2] Liberati A., Altman D.G., Tetzlaff J., et al. The PRISMA statement for reporting systematic reviews and meta-analyses of studies that evaluate health care interventions: explanation and elaboration. *J Clin Epidemiol.* 2009; 62(10): 1–34. DOI: 10.1016/j.jclinepi.2009.06.006
- [3] Shrivage J., Sinha R. A one year randomised clinical trial to study the effect of paracervical block in accelerating the active phase of labour in primigravidas. *J Obstet Gynecol India.* 2001; 51: 71–3.
- [4] Nikkola E., Jahnukainen T., Eklad U., et al. Neonatal monitoring after maternal fentanyl analgesia in labor. *Journal of Clinical Monitoring and Computing.* 2000; 16: 597–608. DOI: 10.1023/a:1012268617009
- [5] Jensen F., Qvist I., Brocks V., et al. Submucous paracervical blockade compared with intramuscular meperidine as analgesia during labor: a doubleblind study. *Obstet Gynecol.* 1984; 64: 724–7.
- [6] Novikova N., Cluver C. Local anaesthetic nerve block for pain management in labour. *Cochrane Database of Systematic Reviews.* 2012. DOI: 10.1002/14651858.CD009200.pub2
- [7] Bendtsen T., Parras T., Moriggl B., et al. Ultrasound-guided pudendal nerve block at the entrance of the pudendal (Alcock) canal: description of anatomy and clinical technique. *Reg Anesth Pain Med.* 2016; 41: 140–5. DOI: 10.1097/AAP.0000000000000355
- [8] Soucy B., Luong D., Michaud J., et al. Accuracy of ultrasound guided pudendal nerve block in the ischial spine and Alcock's canal levels: a cadaveric study. *Pain Med.* 2020; 21: 2692–8. DOI: 10.1093/pm/pnaa136
- [9] Hutchins C. Spinal analgesia for instrumental delivery. A comparison with pudendal nerve block. *Anaesthesia.* 1980; 35: 376–7.
- [10] Nikpoor P., Bain E. Analgesia for forceps delivery. *Cochrane Database of Systematic Reviews.* 2013. DOI: 10.1002/14651858.CD008878.pub2
- [11] Антупин Э.Э., Уваров Д.Н., Недашковский Э.В., Кушев И.П. Эпидуральная анальгезия в первом периоде родов — есть ли альтернатива?

## Conclusion

There are alternative regional methods of labor pain relief in cases where the use of epidural analgesia is contraindicated. All of the above blocks are required to be performed bilaterally using ultrasound navigation for effective labor pain relief, although ESPB has been described monolaterally for labor pain relief [30]. In the literature available to us, we did not find descriptions of additional sedation for performing the blockades described in the review, which most likely indicates that these manipulations do not cause significant discomfort to the patient. At the same time, it is worth noting that some of them (such as paravertebral blockade, pudendal blockade) are better studied than QLB or ESPB. Which of these techniques can become a comparable alternative for labor pain management remains to be seen.

**Funding source.** This study was not supported by any external sources of funding.

**Disclosure.** The authors declare that they have no competing interests.

**Author contribution.** All authors according to the ICMJE criteria participated in the development of the concept of the article, obtaining and analyzing factual data, writing and editing the text of the article, checking and approving the text of the article.

Kochubeynik N.V. — 0000-0002-7990-9991



- тернатива? Анестезиология и реаниматология. 2014; 1: 18–22. [Antipin E.E., Uvarov D.N., Nedashkovsky E.V., Kushev I.P. Epidural analgesia in the first stage of labor — is there an alternative? Anesteziologiya i Reanimatologiya. 2014; 1: 18–22 (In Russ)]
- [12] Неймарк М.И., Иванова О.С. Обоснование целесообразности паравerteбральной блокады для анальгезии самопроизвольных родов. Вестник анестезиологии и реаниматологии. 2018; 15(3): 26–33. DOI: 10.21292/2078-5658-2018-15-3-26-33 [Neymark M.I., Ivanova O.S. Rationale for paravertebral block for analgesia in spontaneous labor. Messenger of Anesthesiology and Resuscitation. 2018; 15(3): 26–33. DOI: 10.21292/2078-5658-2018-15-3-26-33 (In Russ)]
- [13] Eason M.J., Wyatt R. Paravertebral thoracic block—A reappraisal. *Anaesthesia*. 1979; 34: 638–42. DOI: 10.1111/j.1365-2044.1979.tb06363.x
- [14] Shaw W.M. Medial approach for paravertebral somatic nerve block. *J Am Med Assoc*. 1952; 148: 742–4.
- [15] Richardson J., Cheema S.P., Hawkins J., et al. Thoracic paravertebral space location. A new method using pressure measurement. *Anaesthesia*. 1996; 51: 137–9. DOI: 10.1111/j.1365-2044.1996.tb07700.x
- [16] Tenicela R., Pollan S.B. Paravertebral-peridural block technique: A unilateral thoracic block. *Clin J Pain*. 1990; 6: 227–34. DOI: 10.1097/00002508-199009000-00010
- [17] Lang S.A. The use of a nerve stimulator for thoracic paravertebral block. *Anesthesiology*. 2002; 97: 521–2. DOI: 10.1097/00000542-200208000-00037
- [18] Coveney E., Weltz C.R., Greengrass R., et al. Use of paravertebral block anesthesia in the surgical management of breast cancer: Experience in 156 cases. *Ann Surg*. 1998; 227: 496–501. DOI: 10.1097/00000658-199804000-00008
- [19] Lang S.A., Saito T. Thoracic paravertebral nerve block, nerve stimulator guidance and the endothoracic fascia. *Anaesthesia*. 2005; 60: 930–1. DOI: 10.1111/j.1365-2044.2005.04340.x
- [20] Shibata Y., Nishiwaki K. Ultrasound-guided intercostal approach to thoracic paravertebral block. *Anesth Analg*. 2009; 109: 996–7. DOI: 10.1213/ane.0b013e3181af7e7b
- [21] Lichtenstein D., Meziere G., Biderman P., et al. The comet-tail artifact: An ultrasound sign ruling out pneumothorax. *Intensive Care Med*. 1999; 25: 383–8; DOI: 10.1007/s001340050862
- [22] Luyet C., Eichenberger U., Greif R., et al. Ultrasound-guided paravertebral puncture and placement of catheters in human cadavers: an imaging study. *Br J Anaesth*. 2009; 102: 534–9. DOI: 10.1093/bja/aep015
- [23] Cowie B., McGlade D., Ivanusic J., et al. Ultrasound-guided thoracic paravertebral blockade: a cadaveric study. *Anesthesia and Analgesia*. 2010; 110: 1735–9. DOI: 10.1213/ANE.0b013e3181dd58b0
- [24] Uppal V., Sondkoppam R., Sodhi P., et al. Single-injection versus multiple-injection technique of ultrasound-guided paravertebral blocks: a randomized controlled study comparing dermatomal spread. *Reg Anesth Pain Med*. 2017; 42: 575–81. DOI: 10.1097/AAP.0000000000000631
- [25] Luyet C., Siegenthaler A., Szucs-Farkas Z., et al. The location of paravertebral catheters placed using the landmark technique. *Anaesthesia*. 2012; 67: 1321–6. DOI: 10.1111/j.1365-2044.2012.07234.x
- [26] Renes S.H., Bruhn J., Gielen M., et al. In-Plane ultrasound-guided thoracic paravertebral block: a preliminary report of 36 cases with radiologic confirmation of catheter position. *Reg Anesth Pain Med*. 2010; 35: 212–16. DOI: 10.1097/aap.0b013e3181c75a8b
- [27] Forero M., Adhikary S.D., Lopez H., et al. The erector spinae plane block: a novel analgesic technique in thoracic neuropathic pain. *Reg Anesth Pain Med*. 2016; 41: 621–7. DOI: 10.1097/AAP.0000000000000451
- [28] Abu Elyazed M.M., Mostafa S.F., Abdelghany M.S., et al. Ultrasound-guided erector spinae plane block in patients undergoing open epigastric hernia repair: a prospective randomized controlled study. *Anesth Analg*. 2019; 129: 235–40. DOI: 10.1213/ANE.00000000000004071
- [29] Adhikary S.D., Bernard S., Lopez H., et al. Erector spinae plane block versus retrolaminar block: a magnetic resonance imaging and anatomical study. *Reg Anesth Pain Med*. 2018; 43: 756–62. DOI: 10.1097/AAP.0000000000000798
- [30] Vilchis-Renteria J.S., Peng P.W.H., Forero M. The erector spinae plane block for obstetric analgesia: a case series of a novel technique. *Anaesth Rep*. 2020; 8: 170–3. DOI: 10.1002/anr3.12083
- [31] de Haan J., Tabba S., Lee L., et al. Posterior quadratus lumborum block for labor analgesia: a case report. *A A Pract*. 2020; 14(7): e01193. DOI: 10.1213/XAA.00000000000001193
- [32] Borglum J., Gogenur I., Bendtsen T.F. Abdominal wall blocks in adults. *Curr Opin Anaesthesiol*. 2016; 29(5): 638–43. DOI: 10.1097/ACO.0000000000000378
- [33] La Colla L., Uskova A., Ben-David B. Single-shot quadratus lumborum block for postoperative analgesia after minimally invasive hip arthroplasty: a new alternative to continuous lumbar plexus block? *Reg Anesth Pain Med*. 2017; 42: 125–6. DOI: 10.1097/AAP.0000000000000523
- [34] Blanco R., Ansari T., Riad W., et al. Quadratus lumborum block versus transversus abdominis plane block for postoperative pain after cesarean delivery: a randomized controlled trial. *Reg Anesth Pain Med*. 2016; 41(6): 757–62. DOI: 10.1097/AAP.0000000000000495
- [35] Salama E.R. Ultrasound guided bilateral quadratus lumborum block vs. intrathecal morphine for postoperative analgesia after cesarean section: a randomised controlled trial. *Korean J Anesthesiol*. 2019. DOI: 10.4097/kja.d.18.00269
- [36] Sebbag I., Qasem F., Dhir S. Ultrasound guided quadratus lumborum block for analgesia after cesarean delivery: case series. *Rev Bras Anesthesiol*. 2017; 67(4): 418–21. DOI: 10.1016/j.bjan.2017.03.002
- [37] Maenchen N., Hansen C.K., Dam M., et al. Ultrasound-guided transmuscular quadratus lumborum (TQL) block for pain management after caesarean section. *Int J Anesth Anesthesiol*. 2016; 3: 048. DOI: 10.23937/2377-4630/3/2/1048
- [38] Nair A. Bilateral quadratus lumborum block for post-caesarean analgesia. *Indian J Anaesth*. 2017; 61 (4): 362–63. DOI: 10.4103/ija.IJA\_204\_17
- [39] Krohg A., Ullensvang K., Rosseland L.A., et al. The analgesic effect of ultrasound-guided quadratus lumborum block after cesarean delivery: a randomized clinical trial. *Anesth Analg*. 2018; 126(2): 559–65. DOI: 10.1213/ANE.00000000000002648
- [40] Ishio J., Komazawa N., Kido H., et al. Evaluation of ultrasound-guided posterior quadratus lumborum block for postoperative analgesia after laparoscopic gynecologic surgery. *J Clin Anesth*. 2017; 41: 1–4. DOI: 10.1016/j.jclinane.2017.05.015

- [41] *Kadam V.R.* Ultrasound-guided quadratus lumborum block as a postoperative analgesic technique for laparotomy. *J Anaesthesiol Clin Pharmacol.* 2013; 29: 550–2. DOI: 10.4103/0970-9185.119148
- [42] *Visoiu M., Yakovleva N.* Continuous postoperative analgesia via quadratus lumborum block — an alternative to transversus abdominis plane block. *Paediatr Anaesth.* 2013; 23: 959–61. DOI: 10.1111/pan.12240
- [43] *Ueshima H., Hiroshi O.* Intermittent bilateral anterior subcostal quadratus lumborum block for effective analgesia in lower abdominal surgery. *J Clin Anesth.* 2017; 43: 65. DOI: 10.1016/j.jclinane.2017.09.018
- [44] *Chakraborty A., Goswami J., Patro V.* Ultrasound-guided continuous quadratus lumborum block for postoperative analgesia in a pediatric patient. *A A Case Rep.* 2015; 4: 34–6. DOI: 10.1213/XAA.0000000000000090
- [45] *Chakraborty A., Khemka R., Datta T.* Ultrasound-guided truncal blocks: a new frontier in regional anaesthesia. *Indian J Anaesth.* 2016; 60: 703–11. DOI: 10.4103/0019-5049.191665
- [46] *Sindwani G., Sahu S., Suri A., Saeed Z.* Bilateral quadratus lumborum block for postoperative analgesia in a Von Hippel-Lindau syndrome patient undergoing laparoscopic radical nephrectomy. *Saudi J Anaesth.* 2017; 11: 513–4. DOI: 10.4103/sja.SJA\_263\_17
- [47] *Cardoso J.M., Sá M., Reis H., et al.* Type II quadratus lumborum block for a subtotal gastrectomy in a septic patient. *Rev Bras Anesthesiol.* 2016; 68(2): 186–9. DOI: 10.1016/j.bjan.2016.09.009
- [48] *Carvalho R., Segura E., Loureiro M.D., et al.* Quadratus lumborum block in chronic pain after abdominal hernia repair: case report. *Braz J Anesthesiol.* 2017; 67: 107–9. DOI: 10.1016/j.bjane.2014.08.010
- [49] *Öksüz G., Bilal B., Gürkan Y., et al.* Quadratus lumborum block versus transversus abdominis plane block in children undergoing low abdominal surgery: a randomized controlled trial. *Reg Anesth Pain Med.* 2017; 42(5): 674–9. DOI: 10.1097/AAP.0000000000000645
- [50] *Watanabe K., Mitsuda S., Tokumine J., et al.* Quadratus lumborum block for femoral-femoral bypass graft placement: a case report. *Medicine (Baltimore).* 2016; 95(35): e4437. DOI: 10.1097/MD.00000000000004437
- [51] *Ueshima H., Hiroshi O.* Lumbar vertebra surgery performed with a bilateral posterior quadratus lumborum block. *J Clin Anesth.* 2017; 41: 61. DOI: 10.1016/j.jclinane.2017.06.012
- [52] *Iwamitsu R., Ueshima H., Otake H.* Intermittent bilateral posterior quadratus lumborum block was effective for pain management in lumbar spinal fusion. *J Clin Anesth.* 2017; 42: 16. DOI: 10.1016/j.jclinane.2017.08.012